


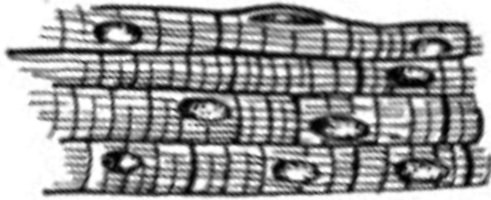
MM Types

Form - Explain

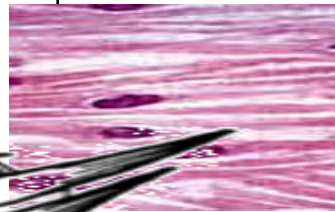
Location

Function^{TOC#12}

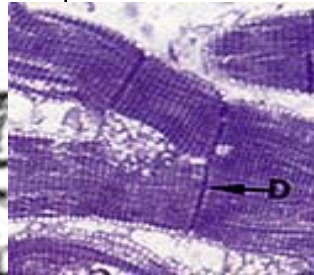
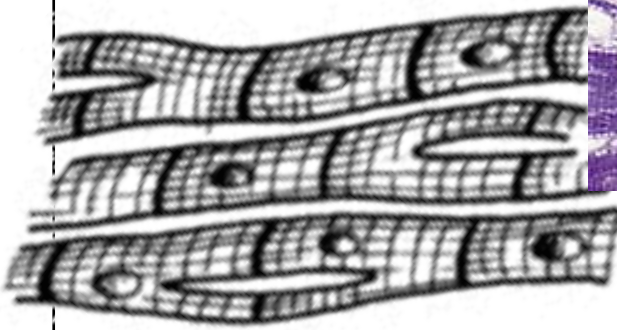
Skeletal Muscle

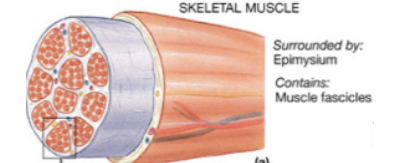
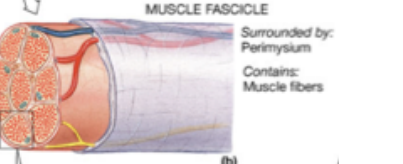

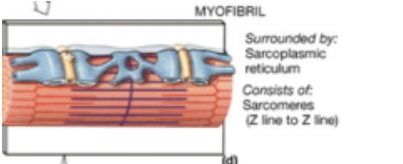
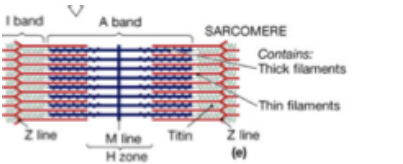
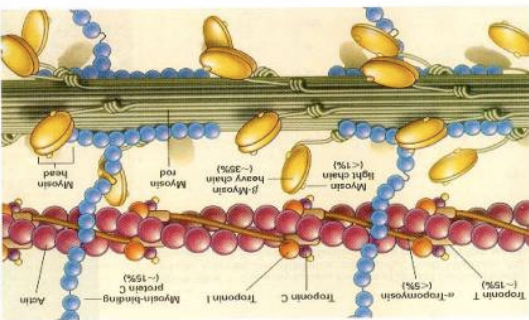
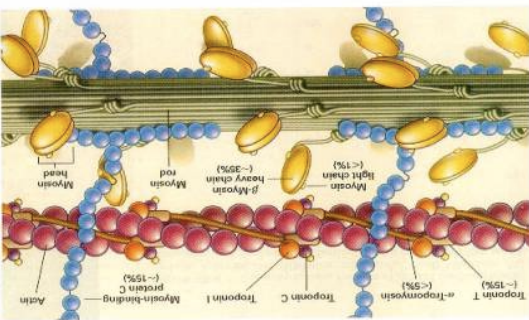


Smooth Muscle



Cardiac Muscle



| TOC#12 MM Structure | Form | Mnemonic Device TOC#12 |
|-------------------------|---|------------------------|
| Muscle |  <p>SKELETAL MUSCLE Surrounded by: Epimysium Contains: Muscle fascicles (a)</p> | |
| Fascicles |  <p>MUSCLE FASCICLE Surrounded by: Perimysium Contains: Muscle fibers (b)</p> | |
| Muscle Fiber (cells) |  <p>MUSCLE FIBER Surrounded by: Endomysium Contains: Myofibrils (c)</p> | |
| Myofibrils |  <p>MYOFIBRIL Surrounded by: Sarcoplasmic reticulum Consists of: Sarcomeres (Z line to Z line) (d)</p> | |
| Sarcomeres |  <p>SARCOMERE Contains: Thick filaments Thin filaments Z line M line Titin Z line I band A band H zone (e)</p> | |
| Myosin Filaments |  | |
| Actin Filaments |  | |